

Brain function in coma, vegetative state, and related disorders

Steven Laureys, Adrian M Owen, and Nicholas D Schiff

We review the nosological criteria and functional neuroanatomical basis for brain death, coma, vegetative state, minimally conscious state, and the locked-in state. Functional neuroimaging is providing new insights into cerebral activity in patients with severe brain damage. Measurements of cerebral metabolism and brain activations in response to sensory stimuli with PET, fMRI, and electrophysiological methods can provide information on the presence, degree, and location of any residual brain function. However, use of these techniques in people with severe brain damage is methodologically complex and needs careful quantitative analysis and interpretation. In addition, ethical frameworks to guide research in these patients must be further developed. At present, clinical examinations identify nosological distinctions needed for accurate diagnosis and prognosis. Neuroimaging techniques remain important tools for clinical research that will extend our understanding of the underlying mechanisms of these disorders.

Lancet Neurol 2004; **3**: 537–46

An accurate and reliable assessment of the arousal and awareness of consciousness in patients with severe brain damage is of greatest importance for their management. Progress in intensive care has led to an increase in the number of patients who survive severe acute brain damage. Although most of these patients recover from coma within the first days after the injury, some permanently lose all brainstem function (brain death), whereas others progress to “wakeful unawareness” (vegetative state). Those who recover typically progress through different stages before fully or partly recovering consciousness (minimally conscious state; figure 1). Clinical practice has shown the challenges of identifying signs of these patients’ conscious perception of the environment and of themselves. Misdiagnoses of vegetative state, minimally conscious state, and locked-in syndrome are common.^{1–6} Bedside assessment of residual brain function in patients who are severely brain-damaged is

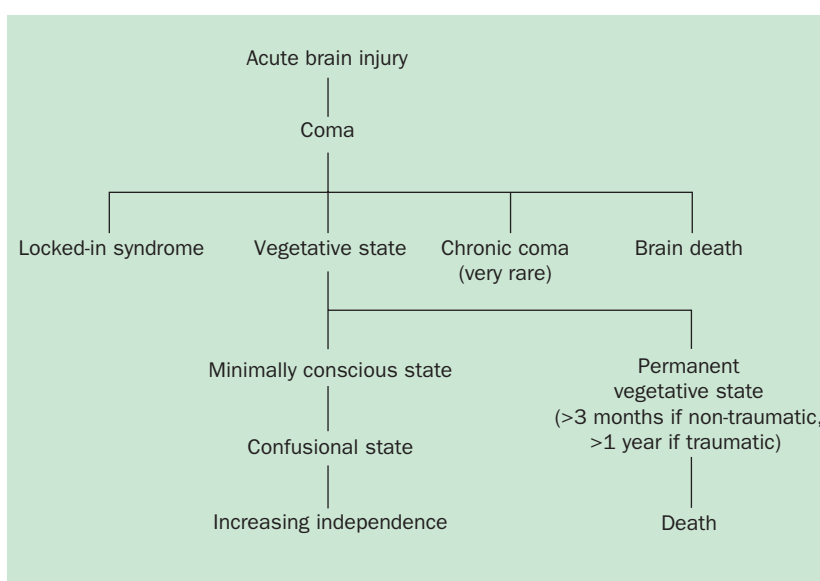


Figure 1. Flow chart of cerebral insult and coma. Vegetative state typically follows a coma; after 1 month the term “persistent vegetative state” is used; after 3 months for a non-traumatic insult or 1 year for a traumatic insult some authors use the term “permanent vegetative state”, which implies no chance of recovery.

difficult because motor responses may be very limited or inconsistent. In addition, consciousness is not an all-or-nothing phenomenon⁷ and its clinical assessment relies on inferences made from responses to external stimuli that are observed at the time of the examination.⁸ In this review we will first define bedside assessment of consciousness. We review the main clinical notions of altered states of consciousness after severe brain damage. Finally, we discuss recent functional neuroimaging findings in patients with these disorders, with a special emphasis on patients in a vegetative state.

SL is at the Belgian National Funds for Scientific Research Cyclotron Research Center and Department of Neurology, University of Liège, Belgium. AMO is at the MRC Cognition and Brain Sciences Unit and Wolfson Brain Imaging Centre, University of Cambridge, UK. NDS is at the Department of Neurology and Neuroscience, Weill Medical College of Cornell University, New York, USA.

Correspondence: Dr Steven Laureys, Consulting Neurologist and Research Associate, Belgian National Funds for Scientific Research, Cyclotron Research Center and Department of Neurology, University of Liège, Sart Tilman B35, 4000 Liège, Belgium. Tel +32 4 366 2316; fax +32 4 366 2946; email steven.laureys@ulg.ac.be

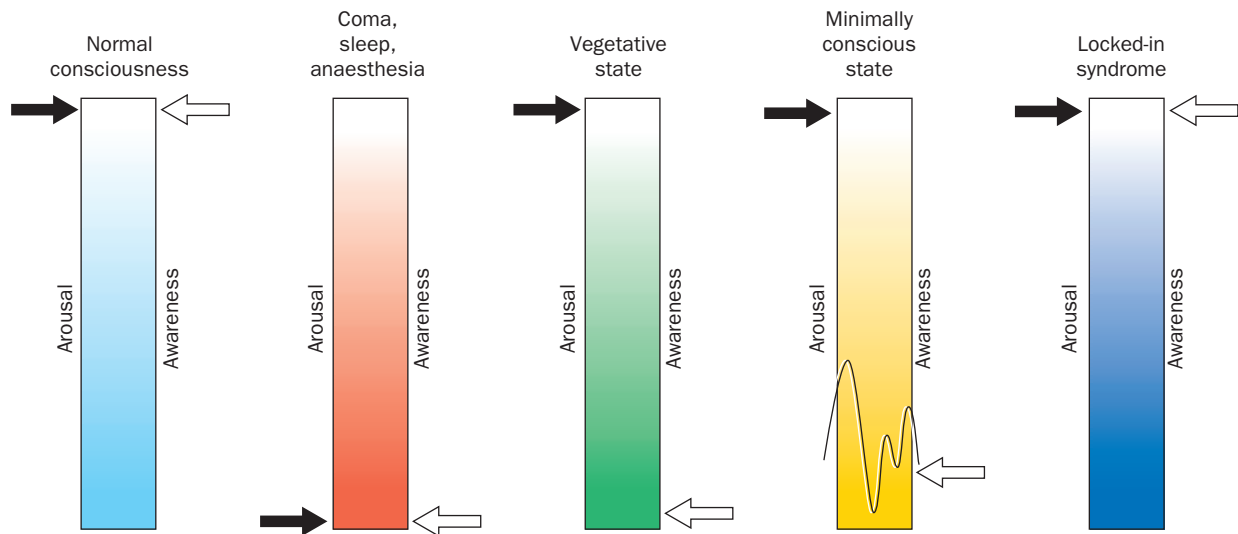


Figure 2. Arousal and awareness, the two components of consciousness in coma, vegetative state, minimally conscious state, and locked-in syndrome.

Consciousness, awareness, and arousal

Consciousness is a multifaceted concept that can be divided into two main components: arousal (ie, wakefulness, or vigilance) and awareness (eg, awareness of the environment and of the self; figure 2).^{9,10} Arousal is supported by several brainstem neuron populations that directly project to both thalamic and cortical neurons.¹¹ Therefore, decline of either the brainstem or both cerebral hemispheres may cause reduced wakefulness. Reflexes are important in the assessment of the functional integrity of the brainstem. However, severe impairment of brainstem reflexes can coexist with intact function of the reticular activating system if the tegmentum of the rostral pons and mesencephalon are unimpaired. Awareness is thought to be dependent upon the functional integrity of the cerebral cortex and its subcortical connections; each of its many parts are located, to some extent, in anatomically defined regions of the brain.^{12,13} Unfortunately, consciousness cannot be measured objectively by any machine. Its estimation requires the interpretation of several clinical signs. Many scoring systems have been developed for the quantification and standardisation of the assessment of consciousness.¹⁴

Clinical definitions

Brain death

The concept of brain death as the death of the individual is largely accepted. Most countries have published recommendations for the diagnosis of brain death but the diagnostic criteria differ from country to country.¹⁵ Some rely on the death of the brainstem only,¹⁶ others require death of the whole brain including the brainstem.¹⁷ However, the clinical assessments for brain death are the same and require the loss of all brainstem reflexes and the demonstration of continuing apnoea in a persistently comatose patient.¹⁸

Coma

Characterised by the absence of arousal and thus also of consciousness, coma is a state of unresponsiveness in which the patient lies with the eyes closed, cannot be aroused, and has no awareness of self and surroundings. Stimulation cannot produce spontaneous periods of wakefulness and eye-opening in patients in a coma, unlike patients in a vegetative state.⁹ To be clearly distinguished from syncope, concussion, or other states of transient unconsciousness, coma must persist for at least 1 h. In general, comatose patients who survive begin to awaken and recover gradually within 2–4 weeks. This recovery may not progress further than a vegetative state or minimally conscious state, or there may be brief or prolonged stages before more complete recovery of consciousness.

Vegetative state

Patients in a vegetative state are awake but are unaware of themselves or their environment.^{19,20} Jennett and Plum¹⁹ cited the Oxford English Dictionary to explain their choice of the term “vegetative”; to vegetate is to “live merely a physical life devoid of intellectual activity or social intercourse” and vegetative describes “an organic body capable of growth and development but devoid of sensation and thought”. “Persistent vegetative state” has been defined as a vegetative state remaining 1 month after acute traumatic or non-traumatic brain damage.²¹ It does not imply irreversibility.²¹ “Permanent vegetative state” is irreversible. According to the Multi-Society Task Force on Permanent Vegetative State, vegetative state may be regarded as permanent 3 months after non-traumatic brain damage or 12 months after traumatic injury. These guidelines are best applied to patients who have diffuse traumatic brain injuries and postanoxic events; outcome in other non-traumatic origins may be less well predicted^{22,23} and further consideration of cause and mechanism are needed in prognosis. Even after long and arbitrary delays,

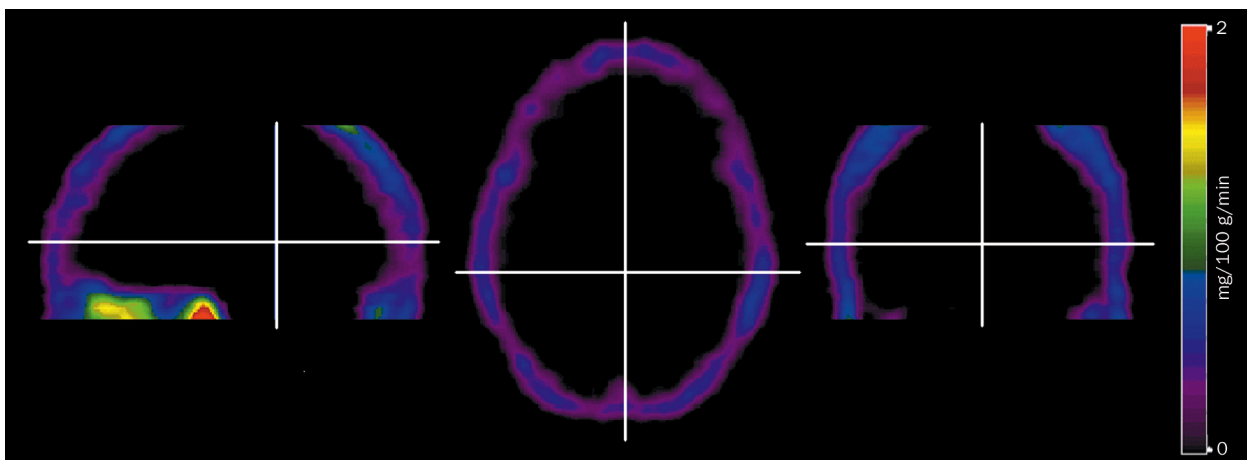


Figure 3. Sagittal (left), transverse (middle), and coronal (right) ^{18}F -fluorodeoxyglucose-PET images of cerebral metabolism in a patient who is brain dead: a picture of an empty skull, similar to “functional decapitation”. The colour scale shows the amount of glucose metabolised per 100 g of brain tissue per minute.

some exceptional patients may show limited recovery. This is more likely in patients with non-traumatic coma without cardiac arrest, who survive in vegetative state for more than 3 months. The diagnosis of vegetative state should be questioned when there is any degree of sustained visual pursuit, consistent and reproducible visual fixation, or response to threatening gestures,²¹ but these responses are observed in some patients who remain in vegetative state for years. It is essential to establish the formal absence of any sign of conscious perception or deliberate action before making the diagnosis.

Minimally conscious state

The Aspen group proposed the criteria for minimally conscious state to categorise patients who are not in a vegetative state but are unable to communicate consistently. To be minimally conscious, patients have to show limited but clear evidence of awareness of themselves or their environment, on a reproducible or sustained basis, by at least one of the following behaviours: following simple commands, gestural or verbal yes/no response (regardless of accuracy), intelligible speech, purposeful behaviour (including movements or affective behaviour that take place in relation to stimuli in the environment and are not due to reflexive activity). Emergence from the minimally conscious state is defined by the ability to communicate or use objects functionally.²⁴ Further improvement is more likely than in patients in a vegetative state.²⁵ However, some people remain in a minimally conscious state permanently. “Akinetic mutism” is a rare state that has been described as a subcategory of the minimally conscious state,²⁶ but other authors suggest that this term should be avoided.²⁷

Locked-in syndrome

The term locked-in syndrome was introduced by Plum and Posner⁹ to describe the quadriplegia and anarthria resulting from the disruption of corticospinal and corticobulbar pathways, respectively. Locked-in syndrome is defined by sustained eye opening (bilateral ptosis should be ruled out as

a complicating factor), awareness of the environment, aphonia or hypophonia, quadriplegia or quadriparesis, and vertical or lateral eye movement or blinking of the upper eyelid to signal yes/no responses.²⁶ Eye or eyelid movements are the main method of communication.

Functional neuroanatomy

Brain death

Brain death results from irreversible loss of brainstem function.²⁸ Functional imaging with cerebral perfusion tracers and single photon emission CT^{29–34} or cerebral metabolism tracers and PET³⁵ typically show a “hollow skull phenomenon” in patients who are brain dead, confirming the absence of neuronal function in the whole brain (figure 3).

Coma

Coma can result from diffuse bihemispheric cortical or white-matter damage after neuronal or axonal injury, or from focal brainstem lesions that affect the pontomesencephalic tegmentum or paramedian thalami bilaterally. On average, grey-matter metabolism is 50–70% of the normal range in comatose patients of traumatic or hypoxic origin.^{36–39} However, in patients with traumatic diffuse axonal injury both hyperglycolysis and metabolic depression have been reported.^{40–43} In patients who recover from a postanoxic coma, cerebral metabolic rates for glucose are 75% of the normal range.⁴⁴ Cerebral metabolism has been shown to correlate poorly with the level of consciousness, as measured by the Glasgow Coma Scale, in patients with mild to severe head injury studied within the first month after head trauma.⁴⁵ New generation PET scanning of patients within 5 days of trauma has shown a correlation between the level of consciousness and regional cerebral metabolism.³⁸ After brain trauma, metabolism was low in the thalamus, brainstem, and cerebellar cortex of comatose survivors compared with that of non-comatose survivors. The mechanisms underlying these changes in cerebral metabolism are not fully understood. At present,

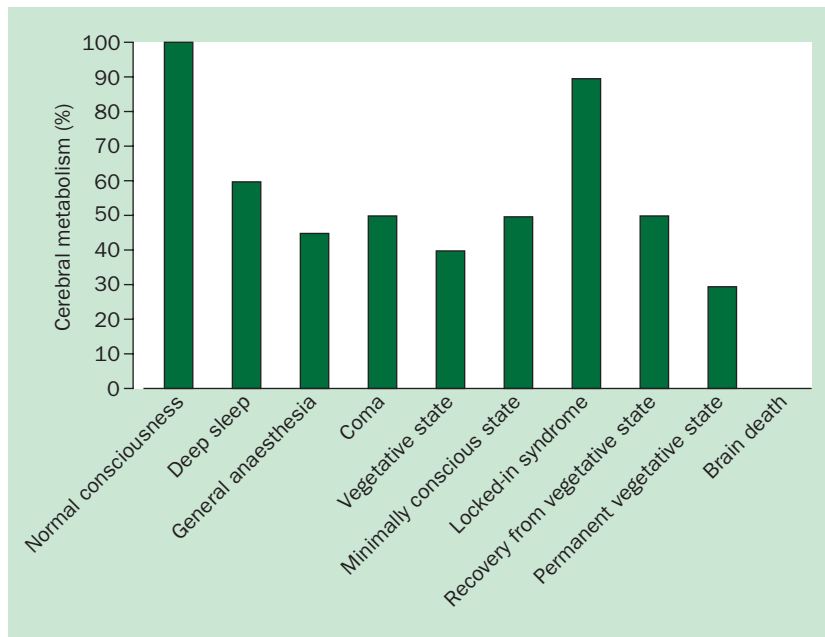


Figure 4. Cerebral metabolism in various states.

there is no established relation between cerebral metabolic rates of glucose or oxygen as measured by PET and patient outcome.

A global decrease in cerebral metabolism is not unique to coma. When different anaesthetics are titrated to the point of unresponsiveness, the reduction in brain metabolism is similar to that in comatose patients.^{46–48} The lowest values of brain metabolism have been reported during propofol anaesthesia (to 28% of the normal range).⁴⁶ A transient decrease in brain metabolism also takes place during deep sleep (stage III and IV),^{49,50} where cortical cerebral metabolism can drop to nearly 40% of the normal range of values (figure 4).

Vegetative state

Resting brain function

In a vegetative state the brainstem is mostly spared whereas the grey and white matter of both cerebral hemispheres are widely and severely damaged. Overall cortical metabolism of patients in a vegetative state is 40–50% of the normal range of values.^{37,44,51–60} However, some studies, have found that cerebral metabolism⁵⁷ or blood flow⁶¹ is in the normal range in patients in a vegetative state. In “permanent” vegetative state (ie, 12 months after a trauma or 3 months after non-traumatic brain damage), brain metabolism values drop to 30–40% of the normal range of values.³⁷ This loss of metabolic function over time is the result of progressive Wallerian and trans-synaptic neuronal degeneration. A relative sparing of metabolism in the brainstem and allied structures (encompassing the pedunculopontine reticular formation, the hypothalamus, and the basal forebrain) is characteristic of patients in a vegetative state.⁶² The functional preservation of these structures maintains arousal and autonomic functions in these patients. The other hallmark of the vegetative state is a systematic impairment of

metabolism in the polymodal associative cortices (bilateral prefrontal regions, Broca’s area, parietotemporal, and posterior parietal areas and precuneus).⁵⁸ These regions are important in various functions that are necessary for consciousness, such as attention, memory, and language.⁶³ It is not known whether the observed metabolic impairment in this large cortical network reflects an irreversible structural neuronal loss,⁶⁴ or functional and potentially reversible damage. However, in rare cases where patients in a vegetative state recover awareness of self and environment, PET shows a functional recovery of metabolism in these same cortical regions.⁵⁹ Moreover, the resumption of long-range functional connectivity between these associative cortices⁵⁸ and between some of these and the intralaminar thalamic nuclei parallels the restoration of their functional

integrity.⁶⁵ The cellular mechanisms that underlie this functional normalisation remain putative: axonal sprouting, neurite outgrowth, cell division (known to occur predominantly in associative cortices in healthy primates)⁶⁶ have been proposed as candidate processes.⁶⁷ The challenge is now to identify the conditions and the mechanisms by which, some patients may recover consciousness.

Brain activation studies

An auditory paradigm was used in the first oxygen-15-labelled PET study of a patient in a vegetative state. The authors observed activation in anterior cingulate and temporal cortices when this patient (in a post-traumatic vegetative state) was told a story by his mother compared with when he heard nonsense words.⁶⁸ They interpreted this activation as the processing of the emotional attributes of speech or sound. In another widely discussed PET study of a patient in an upper boundary vegetative state or lower boundary minimally conscious state after encephalitis (and before subsequent recovery), activation during presentation of photographs of familiar faces was compared with that during meaningless pictures. Although there was no evidence of behavioural responsiveness during presentation of the familiar-face photographs except occasional visual tracking, the visual association areas encompassing the fusiform face area showed significant activation.²² In cohort studies of patients unambiguously meeting the clinical diagnosis of vegetative state, simple noxious somatosensory⁶⁹ and auditory^{60,70} stimuli have shown systematic activation of primary sensory cortices and lack of activation in higher order associative cortices from which they were functionally disconnected. High intensity noxious electrical stimulation activated midbrain, contralateral thalamus, and primary somatosensory cortex in each and every one of the 15 patients studied, even in the absence of cortical evoked

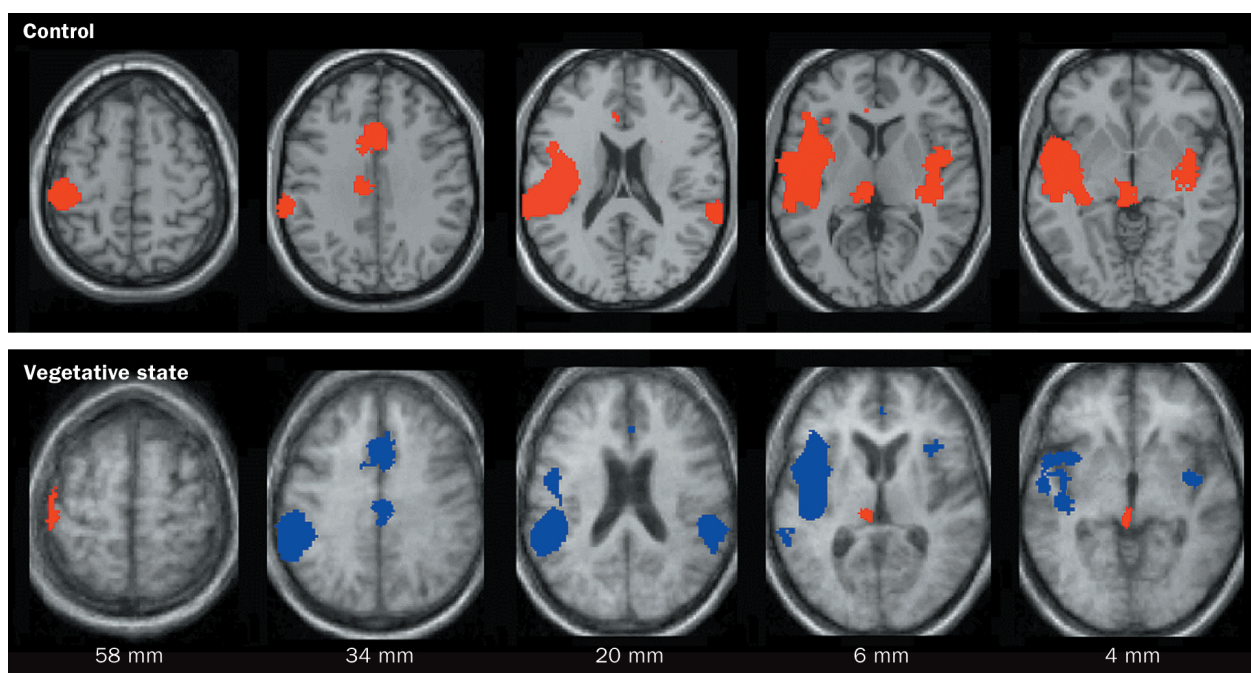


Figure 5. Pain perception in vegetative state. Top: Brain regions that were activated during noxious stimulation in controls are shown in red. Bottom: Brain regions that activated during stimulation in patients in vegetative state are shown in red and regions that activated less in patients than in controls are shown in blue. Regions of activation are projected on transverse sections of a normalised brain MRI template in controls and on the mean MRI of the patients (distances are relative to the bicommissural plane). Reproduced with permission from Elsevier.⁶⁹

potentials.⁶⁹ However, secondary somatosensory, insular, posterior parietal, and anterior cingulate cortices, which were activated in all control individuals, did not show significant activation in any patient (figure 5). Moreover, in patients in a vegetative state, the activated primary somatosensory cortex was functionally disconnected from higher-order associative cortices of the pain-matrix. Similarly, although simple auditory stimuli activated bilateral primary auditory cortices, higher-order multimodal association cortices were not activated. Moreover, a cascade of functional disconnections were observed along the auditory cortical pathways, from primary auditory areas to multimodal and limbic areas,⁷⁰ suggesting that the observed residual cortical processing in the vegetative state does not lead to integrative processes, which are thought to be necessary for awareness.

Patients in a vegetative state with atypical behavioural fragments

Stereotyped responses to external stimuli—such as grimacing, crying, or occasional vocalisation—are common in patients in a vegetative state. These behaviours are assumed to come from brainstem circuits and limbic cortical regions that are preserved. Rarely, however, patients meeting the diagnostic criteria for vegetative state have behavioural features that seem to contravene the diagnosis. From a series of multimodal imaging studies of patients in a vegetative state, three with unusual behavioural fragments were identified. Preserved areas of high resting brain metabolism (measured with fluorine-18-labelled deoxyglucose PET) and incompletely preserved gamma-band responses (measured

with magnetoencephalography) were fitted to structural data from an MRI and correlated with the behaviours of the patients.⁵⁷ Among those studied was a patient who had been in a vegetative state for 20 years who infrequently expressed single words unrelated to any environmental stimuli.⁷¹ MRI images showed severe subcortical damage. Resting ¹⁸F-fluorodeoxyglucose-PET measurements of the patient's brain showed a global cerebral metabolic rate of <50% of the normal range across most brain regions, with small regions in the left hemisphere expressing higher levels of metabolism. Magnetoencephalography responses to bilateral auditory stimulation were confined to the left hemisphere and localised to primary auditory areas (figure 6). Taken together, the imaging and neurophysiological data seemed to show that the left sided thalamocortical–basal ganglia loops (that support language function in Heschl's gyrus, Broca's area, and Wernicke's area) were partially preserved. Similar observations in two other patients in chronic vegetative state provide evidence that isolated cerebral networks may remain active in rare cases. The preservation of these isolated behaviours does not indicate further recovery in patients in chronic vegetative state who have been repeatedly examined and carefully studied with imaging tools. Reliable observations of such unusual features should prompt further investigation in individual cases.

Minimally conscious state

Because criteria for the minimally conscious state are new, there are very few functional imaging studies of patients in this condition. Preliminary data show that overall cerebral metabolism is decreased to values slightly higher but

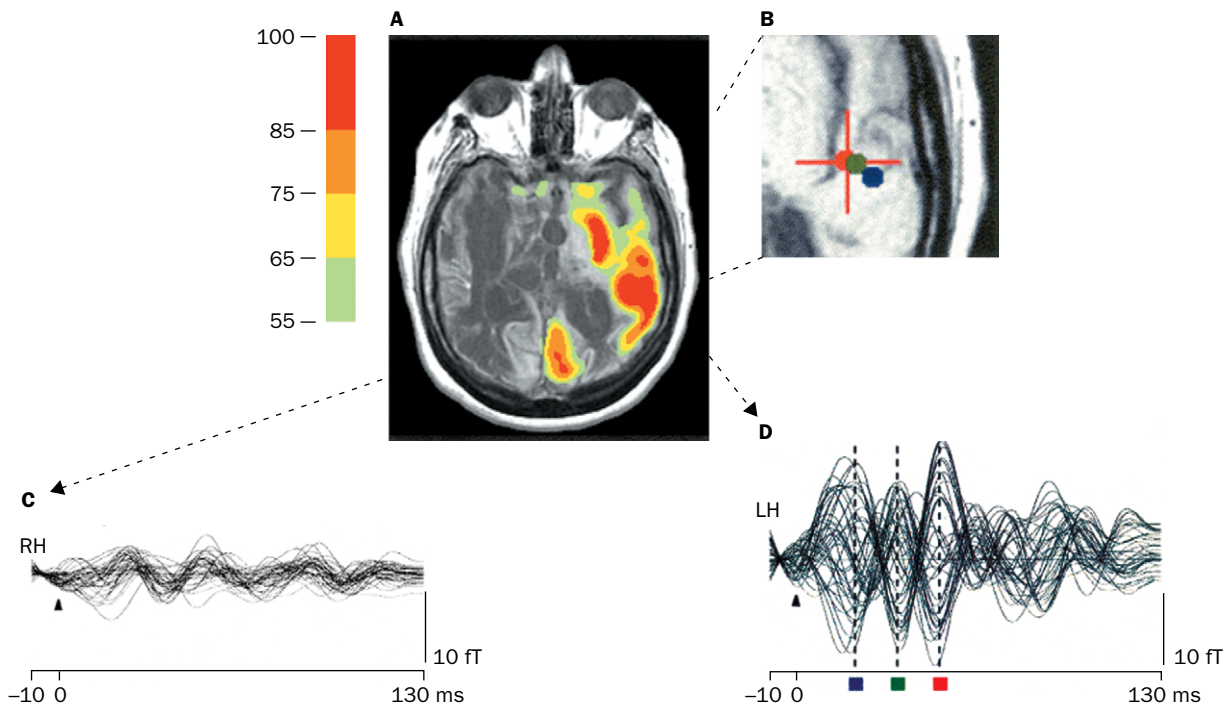


Figure 6. A: Preservation of regional cerebral metabolic activity in a patient in vegetative state who occasionally produces individual words. ^{18}F -fluorodeoxyglucose-PET data (referenced to MRI⁶⁷) is overlaid with calculated magnetoencephalogram equivalent current dipoles that identify the source of the signal.⁷¹ PET voxels are normalised by region and shown on a scale ranging from 55% to 100% of normal. B: MEG dipole locations. Dipole location of maximum response at a latency of 50 ms is shown with the cross hair and red dot. Dipole fits at latencies of 21 ms and 35 ms are shown with the blue and green dots respectively. C: MEG waveforms for right hemisphere gamma-band (20–50 Hz filtered) midlatency evoked activity in response to bilateral auditory stimulation. D: MEG waveforms for left hemisphere gamma-band (20–50 Hz filtered) midlatency evoked activity in response to bilateral auditory stimulation. Limited preservation of left sided auditory midlatency evoked response supports the inference of a preserved isolated cerebral network within the left hemisphere.

comparable to those observed in the vegetative state. The medial parietal cortex (precuneus) and adjacent posterior cingulate cortex seem to be brain regions that differentiate patients in minimally conscious state from those in vegetative state.⁷² Interestingly, these areas are among the most active brain regions in conscious waking^{49,73,74} and are among the least active regions in altered states of consciousness such as halothane⁴⁸ or propofol^{75,76} induced general anaesthesia, sleep,^{49,77} hypnotic state,^{78,79} dementia,^{80,81} and Wernicke–Korsakoff's or postanoxic amnesia.⁸² This richly connected⁸³ multimodal posteromedial associative area may be part of the neural network subserving human awareness (figure 7).^{63,74,84}

Simple auditory stimulation induced more widespread activation in minimally conscious state than in vegetative state.⁶⁰ In the former, activation included primary areas as well as auditory associative areas suggesting more complex processing. Moreover, corticocortical functional connectivity was more efficient in the minimally conscious state, compared with the vegetative state, between auditory cortex and a large network of temporal and prefrontal cortices. Such findings encourage ongoing developments of neuromodulatory and cognitive revalidation therapeutic strategies in patients in a minimally conscious state.⁸⁵

Recent research used fMRI to study the response of patients in a minimally conscious state to natural language stimuli (ie, sentences read at conversational rate by a human

voice); patients and controls heard narratives that had personally meaningful content read forwards and in reverse by a familiar voice.⁸⁶ (The physical properties of the sounds mostly remained the same when the narrative was heard in reverse.) When the narratives were read forwards, components of the cortical language networks showed selective activation in the two patients studied. Controls activated the same networks when they heard the narratives read backwards as when they heard them read forwards, but the patients in a minimally conscious state did not. These findings correlate with low resting metabolic activity and suggest that the capacity to activate large integrative networks remains in some minimally conscious state patients. Preservation of large-scale networks in patients in minimally conscious state may underlie rare instances of their late recoveries of verbal fluency.⁸⁷

Locked-in syndrome

Structural brain imaging with MRI may show isolated lesions (bilateral infarction, haemorrhage, or tumour) of the ventral portion of the basis pontis or midbrain. According to some authors, EEG and evoked potentials do not reliably distinguish the locked-in syndrome from the vegetative state.⁸⁸ PET scanning has shown high metabolic levels in the brains of patients in a locked-in syndrome compared to those in a vegetative state.⁵¹ Moreover, preliminary voxel-based statistical analyses show that no supratentorial cortical

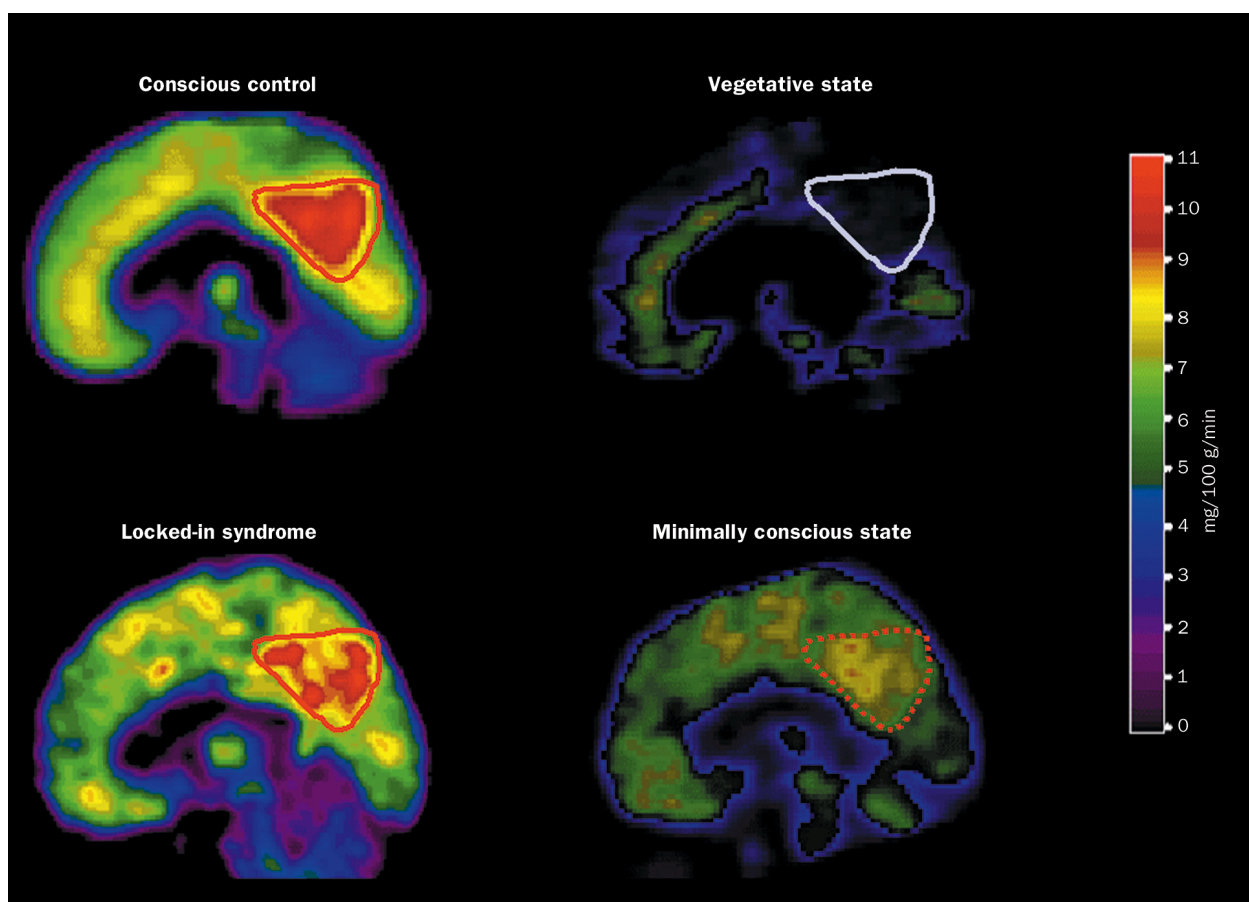


Figure 7. Resting cerebral metabolism in healthy individuals and patients in vegetative state, locked-in syndrome, and minimally conscious state. Images are shown in the sagittal plane with the same colour scale (mg glucose metabolised per 100 g of brain tissue per minute). Note that in healthy (conscious) individuals the medial posterior cortex (encompassing the precuneus and adjacent posterior cingulate cortex, shown with a red line) is the most active region of the brain metabolically; in patients in vegetative state who wake, this same area (shown with a blue line) is the least active region metabolically. In the locked-in syndrome, no supratentorial brain region shows substantial decreases in metabolism. The precuneus and posterior cingulate cortex of patients in minimally conscious state show an intermediate metabolism, higher than in a vegetative state, but lower than in healthy (conscious) individuals. We hypothesise that this region represents part of the neural network subserving consciousness.

areas show a significantly lower metabolism in patients in a locked-in syndrome when compared with healthy controls.⁸⁹ These findings emphasise the need to quickly make the diagnosis and recognise the terrifying situation of patients with intact awareness of self and environment in acutely locked-in, immobile bodies. Health-care workers should take into account the intense emotional state of patients with acute locked-in syndrome, adapt their bedside behaviour and consider pharmacological anxiolytic therapy. With appropriate medical care, life expectancy may be several decades and even if the chances of motor recovery are very limited, computer-based communication methods have substantially improved the quality of life in chronic locked-in syndrome.^{5,90}

Methodological issues

The acquisition, analysis, and interpretation of neuroimaging data from patients with severe brain damage is complex.^{91–93} In quantitative PET studies, the absolute value of cerebral metabolic rates depends on many assumptions, and in cases of cerebral pathology a consensus has not been established. For

example, the estimation of the cerebral metabolic rate of glucose using ¹⁸F-fluorodeoxyglucose PET requires a correction factor, known as the lumped constant. This lumped constant is stable in the brains of healthy people. However, in traumatic brain injury, a global decrease in the lumped constant has been reported⁹⁴ and in severe cerebral ischaemia, regional lumped constant values increase as a result of glucose transport limitation.⁹⁵ Second, cerebral glucose use as measured by PET may not always be as tightly coupled with oxygen use in patients because metabolic changes, including anaerobic glycolysis, may occur after brain damage.^{42,96,97} Third, because PET provides measurements per unit volume of brain tissue, these scans may be affected by the inclusion of metabolically inactive spaces, such as CSF or by brain atrophy, which may artificially lower the calculated cerebral metabolism.^{98–102}

Although metabolic studies are useful, they can only identify functionality at the most general level; that is, mapping cortical and subcortical regions that may be involved in cognitive processes, rather than relating neural activity within such regions to specific cognitive processes.

Search strategy and selection criteria

References were identified by PubMed searches with the terms "brain death", "coma", "vegetative state", "minimally conscious state", or "locked-in syndrome" combined with "positron emission tomography", "magnetoencephalography", or "functional magnetic resonance imaging". Only studies of adults published in English were used. The references in these papers were also included. References were selected on the basis of relevance and accessibility. Abstracts and reports from meetings were included only when they related directly to previously published work. We excluded studies in which the clinical details were insufficient to guarantee accuracy of diagnoses.

Together with established sensory paradigms, $H_2^{15}O$ -PET, fMRI, or magnetoencephalography activation studies may be a viable method for the assessment of cognitive processing or potentially recruitable populations of neurons in patients with severe brain damage. However, like metabolic studies, these investigations are methodologically complex and the results are often equivocal. For example, in patients with brain damage the coupling of neuronal activity and local haemodynamics, essential for all $H_2^{15}O$ -PET and fMRI activation measurements, is likely to be different from that in healthy controls,^{103–106} making interpretation of such data sets extremely difficult. Notwithstanding this basic methodological concern, the choice of the experiment is also crucial. For example, if brainstem auditory evoked responses are abnormal, auditory stimuli may be inappropriate and alternative stimuli—such as visual stimuli—should be considered. The investigation should also be complex enough that the cognitive processes of interest will be studied (ie, preferably beyond stimulus perception), yet not so complex that the tasks could easily overload the cognitive capacities of a tired or inattentive patient. In addition, so that the imaging data obtained from patients can be interpreted, the investigation must produce well documented, anatomically specific, robust, and reproducible activation patterns in healthy volunteers. In vegetative state, minimally conscious state, and locked-in syndrome, episodes of low arousal and sleep are common and close patient monitoring—preferably through EEG recording—during activation scans is essential so that these periods can be avoided. Spontaneous movements during the scan itself may also compromise the interpretation of functional neuroimaging data, particularly with fMRI scans.¹⁰⁷ Processing of functional neuroimaging data may also present challenging problems in patients with acute brain damage. For example, the presence of gross hydrocephalus or focal pathology may complicate the fitting of functional imaging data to structural imaging data, and the normalisation of these images through reference to a healthy brain.¹⁰⁸ Under these circumstances, statistical assessment of activation patterns is complex and interpretation of activation foci with standard stereotaxic coordinates may be impossible. Finally, as for all PET studies in human beings, issues of radiation exposure must be considered and may preclude longitudinal or follow-up studies of these patients.

In summary, metabolic and molecular¹⁰⁹ studies with PET and activation studies with PET, fMRI, or magnetoencephalography provide exciting new opportunities in the assessment of patients with severe brain damage. However, all of these techniques are methodologically complex with many problems of analysis and interpretation. Therefore, for the foreseeable future, functional imaging will complement rather than replace standardised, repeated clinical assessment by experienced and appropriately qualified personnel.

Ethical issues

Patients with severe brain damage who are unable to communicate present several ethical concerns.^{110–113} Foremost is the concern that diagnostic and prognostic accuracy is certain, as treatment decisions typically include the possibility of withdrawal of life-support.^{20,114} Although imaging techniques have the potential to improve both diagnostic and prognostic accuracy, careful and repeated neurological assessment by a trained examiner remains best practice. Accurate clinical assessments of patients in these conditions must be obtained before they undergo neuroimaging. Moreover, in reports of neuroimaging studies, all relevant clinical details must be available for comparisons between studies.

Ethical concerns are commonly raised about the participation of patients with severe brain damage in neuroimaging studies. By definition, unconscious or minimally conscious patients cannot give informed consent to participate in clinical research and written approval must typically be obtained from family or legal representatives depending on governmental and hospital guidelines. Nonetheless, researchers studying these patients have been refused grants, ethics committee approval, and research publication; these decisions tend to be made on the basis that studies of patients who cannot provide consent are unethical. We prefer an ethical framework that balances access to research with medical advances alongside protection for defenceless patients.¹¹⁵ Severe brain damage represents an immense social and economic problem that warrants further research. Unconscious, minimally conscious, and locked-in patients deserve special procedural protections. However, it is important to stress that they are also at risk of being denied therapy that may be life-saving if clinical research cannot be done on these patient groups.

Conclusion

Patients who are in coma, vegetative state, minimally conscious state, or locked-in syndrome present unique problems for diagnosis, prognosis, treatment, and everyday management. At the patient's bedside, assessment of cognitive function is difficult because voluntary movements may be very small, inconsistent, and easily exhausted. Functional neuroimaging will never replace the clinical assessment of patients with altered states of consciousness. Nevertheless, using population norms it can provide an objective measure of the regional distribution of cerebral activity at rest and under various conditions of

stimulation. The quantification of brain activity differentiates patients who sometimes only differ by a brief and small movement of a finger. In our opinion, PET, magnetoencephalography, EEG, and especially fMRI will increase substantially our understanding of patients with severe brain damage.

Authors' contributions

SL did the general review plan and the reference search, contributed to all sections, and made figures 1–5 and 7. AMO reviewed the general review plan as well as the sections on methodology and functional neuroanatomy, and made comments and amendments throughout

revision of the article. NDS reviewed the general review plan, contributed to the literature search and all sections, and made figure 6.

Conflict of interest

We have no conflicts of interest.

Role of the funding source

SL is a research associate at the Fonds National de la Recherche Scientifique (FNRS) and is supported by FNRS grants 3.4517.04 and by grants from the Fondation Médicale Reine Elisabeth, the Centre Hospitalier Universitaire Sart Tilman, the University of Liège, and the Mind Science Foundation. NDS is supported by NS02172, NS43451, and the Charles A Dana Foundation.

References

- Andrews K, Murphy L, Munday R, Littlewood C. Misdiagnosis of the vegetative state: retrospective study in a rehabilitation unit. *BMJ* 1996; 313: 13–16.
- Childs NL, Mercer WN, Childs HW. Accuracy of diagnosis of persistent vegetative state. *Neurology* 1993; 43: 1465–67.
- Ostrum AE. The 'locked-in' syndrome—comments from a survivor. *Brain Inj* 1994; 8: 95–98.
- Tresch DD, Sims FH, Duthie EH, Goldstein MD, Lane PS. Clinical characteristics of patients in the persistent vegetative state. *Arch Intern Med* 1991; 151: 930–12.
- Vigand P, Vigand S. Only the eyes say yes. New York: Arcade Publishing, 2000.
- Bauby JD. The diving bell and the butterfly. New York: Knopf, 1997.
- Bernat JL. The boundaries of the persistent vegetative state. *J Clin Ethics* 1992; 3: 176–80.
- Wade DT, Johnston C. The permanent vegetative state: practical guidance on diagnosis and management. *BMJ* 1999; 319: 841–44.
- Plum F, Posner JB. The diagnosis of stupor and coma (3rd edn). Philadelphia: FA Davis, 1983.
- Zeman AZ, Grayling AC, Cowey A. Contemporary theories of consciousness. *J Neurol Neurosurg Psychiatry* 1997; 62: 549–52.
- Steriade M, Jones EG, McCormick D. *Thalamus*. New York: Elsevier, 1997.
- Dehaene S, Naccache L. Towards a cognitive neuroscience of consciousness: basic evidence and a workspace framework. *Cognition* 2001; 79: 1–37.
- Zeman A. Consciousness. *Brain* 2001; 124: 1263–89.
- Laureys S, Majerus S, Moonen G. Assessing consciousness in critically ill patients. In: Vincent JL, ed. 2002 Yearbook of Intensive Care and Emergency Medicine. Heidelberg: Springer-Verlag, 2002: 715–27.
- Haupt WF, Rudolf J. European brain death codes: a comparison of national guidelines. *J Neurol* 1999; 246: 432–37.
- Medical Royal Colleges and their Faculties in the United Kingdom. Diagnosis of brain death. *BMJ* 1976; 2: 1187–88.
- The Quality Standards Subcommittee of the American Academy of Neurology. Practice parameters for determining brain death in adults (summary statement). *Neurology* 1995; 45: 1012–14.
- Medical Consultants on the Diagnosis of Death. Guidelines for the determination of death: report of the medical consultants on the diagnosis of death to the president's commission for the Study of Ethical Problems in Medicine and Biomedical and Behavioral Research. *JAMA* 1981; 246: 2184–86.
- Jennett B, Plum F. Persistent vegetative state after brain damage: a syndrome in search of a name. *Lancet* 1972; 1: 734–37.
- Jennett B. The vegetative state: medical facts, ethical and legal dilemmas. Cambridge: Cambridge University Press, 2002.
- The Multi-Society Task Force on Persistent Vegetative State. Medical aspects of the persistent vegetative state (1). *N Engl J Med* 1994; 330: 1499–508.
- Menon DK, Owen AM, Williams EJ, et al. Cortical processing in persistent vegetative state. *Lancet* 1998; 352: 200.
- Wilson BA, Gracey F, Bainbridge K. Cognitive recovery from "persistent vegetative state": psychological and personal perspectives. *Brain Inj* 2001; 15: 1083–92.
- Giacino JT, Ashwal S, Childs N, et al. The minimally conscious state: definition and diagnostic criteria. *Neurology* 2002; 58: 349–53.
- Giacino JT. Disorders of consciousness: differential diagnosis and neuropathologic features. *Semin Neurol* 1997; 17: 105–11.
- American Congress of Rehabilitation Medicine. Recommendations for use of uniform nomenclature pertinent to patients with severe alterations of consciousness. *Arch Phys Med Rehabil* 1995; 76: 205–9.
- ANA Committee on Ethical Affairs. Persistent vegetative state: report of the American Neurological Association Committee on Ethical Affairs. *Ann Neurol* 1993; 33: 386–90.
- Wijdicks EF. The diagnosis of brain death. *N Engl J Med* 2001; 344: 1215–21.
- Facco E, Zucchetta P, Munari M, et al. 99mTc-HMPAO SPECT in the diagnosis of brain death. *Intensive Care Med* 1998; 24: 911–17.
- Bonetti MG, Ciritella P, Valle G, Perrone E. 99mTc HM-PAO brain perfusion SPECT in brain death. *Neuroradiology* 1995; 37: 365–69.
- Wieler H, Marohl K, Kaiser KP, Klawki P, Frossler H. Tc-99m HMPAO cerebral scintigraphy: a reliable, noninvasive method for determination of brain death. *Clin Nucl Med* 1993; 18: 104–09.
- Laurin NR, Driedger AA, Hurwitz GA, et al. Cerebral perfusion imaging with technetium-99m HM-PAO in brain death and severe central nervous system injury. *J Nucl Med* 1989; 30: 1627–35.
- Yatim A, Mercatello A, Coronel B, et al. 99mTc-HMPAO cerebral scintigraphy in the diagnosis of brain death. *Transplant Proc* 1991; 23: 2491.
- Roine RO, Launes J, Lindroth L, Nikkinen P. 99mTc-hexamethylpropyleneamine oxime scans to confirm brain death. *Lancet* 1986; 2: 1223–24.
- Meyer MA. Evaluating brain death with positron emission tomography: case report on dynamic imaging of 18F-fluorodeoxyglucose activity after intravenous bolus injection. *J Neuroimaging* 1996; 6: 117–19.
- Schaafsma A, de Jong BM, Bams JL, Haaxma-Reiche H, Pruijm J, Zijlstra JG. Cerebral perfusion and metabolism in resuscitated patients with severe post-hypoxic encephalopathy. *J Neurol Sci* 2003; 210: 23–30.
- Tommasino C, Grana C, Lucignani G, Torri G, Fazio F. Regional cerebral metabolism of glucose in comatose and vegetative state patients. *J Neurosurg Anesthesiol* 1995; 7: 109–16.
- Hattori N, Huang SC, Wu HM, et al. Correlation of regional metabolic rates of glucose with glasgow coma scale after traumatic brain injury. *J Nucl Med* 2003; 44: 1709–16.
- Bergsneider M, Hovda DA, McArthur DL, et al. Metabolic recovery following human traumatic brain injury based on FDG-PET: time course and relationship to neurological disability. *J Head Trauma Rehabil* 2001; 16: 135–48.
- Tenjin H, Ueda S, Mizukawa N, et al. Positron emission tomographic studies on cerebral hemodynamics in patients with cerebral contusion. *Neurosurgery* 1990; 26: 971–79.
- Yamaki T, Imahori Y, Ohmori Y, et al. Cerebral hemodynamics and metabolism of severe diffuse brain injury measured by PET. *J Nucl Med* 1996; 37: 1166–70.
- Bergsneider M, Hovda DA, Shalmon E, et al. Cerebral hyperglycolysis following severe traumatic brain injury in humans: a positron emission tomography study. *J Neurosurg* 1997; 86: 241–51.
- Hutchinson PJ, Gupta AK, Fryer TF, et al. Correlation between cerebral blood flow, substrate delivery, and metabolism in head injury: a combined microdialysis and triple oxygen positron emission tomography study. *J Cereb Blood Flow Metab* 2002; 22: 735–45.
- DeVolder AG, Goffinet AM, Bol A, Michel C, de Barys T, Laterre C. Brain glucose metabolism in postanoxic syndrome: positron emission tomographic study. *Arch Neurol* 1990; 47: 197–204.
- Bergsneider M, Hovda DA, Lee SM, et al. Dissociation of cerebral glucose metabolism and level of consciousness during the period of metabolic depression following human traumatic brain injury. *J Neurotrauma* 2000; 17: 389–401.
- Alkire MT, Haier RJ, Barker SJ, Shah NK, Wu JC, Kao YJ. Cerebral metabolism during propofol anesthesia in humans studied with positron emission tomography. *Anesthesiology* 1995; 82: 393–403.
- Alkire MT, Haier RJ, Shah NK, Anderson CT. Positron emission tomography study of regional cerebral metabolism in humans during isoflurane anesthesia. *Anesthesiology* 1997; 86: 549–57.
- Alkire MT, Pomfret CJ, Haier RJ, et al. Functional brain imaging during anesthesia in humans: effects of halothane on global and regional cerebral glucose metabolism. *Anesthesiology* 1999; 90: 701–09.
- Maquet P, Degeldre C, Delfiore G, et al. Functional neuroanatomy of human slow wave sleep. *J Neurosci* 1997; 17: 2807–12.
- Buchsbaum MS, Gillin JC, Wu J, et al. Regional cerebral glucose metabolic rate in human sleep assessed by positron emission tomography. *Life Sci* 1989; 45: 1349–56.
- Levy DE, Sidtis JJ, Rottenberg DA, et al. Differences in cerebral blood flow and glucose utilization in vegetative versus locked-in patients. *Ann Neurol* 1987; 22: 673–82.
- Rudolf J, Ghaemi M, Haupt WF, Szelies B, Heiss WD. Cerebral glucose metabolism in acute and persistent vegetative state. *J Neurosurg Anesthesiol* 1999; 11: 17–24.
- Momose T, Matsui T, Kosaka N. Effect of cervical spinal cord stimulation (cSCS) on cerebral glucose metabolism and blood flow in a vegetative patient assessed by positron emission tomography (PET) and single photon emission computed tomography (SPECT). *Radiat Med* 1989; 7: 243–46.
- Rudolf J, Sobesky J, Ghaemi M, Heiss WD. The correlation between cerebral glucose metabolism and benzodiazepine receptor density in the acute vegetative state. *Eur J Neurol* 2002; 9: 671–77.
- Edgren E, Enblad P, Grenvik A, et al. Cerebral blood flow and metabolism after cardiopulmonary resuscitation: a pathophysiologic and prognostic positron emission tomography pilot study. *Resuscitation* 2003; 57: 161–70.
- Beuthien-Baumann B, Handrick W, Schmidt T, et al. Persistent vegetative state: evaluation of brain metabolism and brain perfusion with PET and SPECT. *Nucl Med Commun* 2003; 24: 643–49.
- Schiff ND, Ribary U, Moreno DR, et al. Residual cerebral activity and behavioural fragments can remain in the persistently vegetative brain. *Brain* 2002; 125: 1210–34.
- Laureys S, Goldman S, Phillips C, et al. Impaired effective cortical connectivity in vegetative state: preliminary investigation using PET. *Neuroimage* 1999; 9: 377–82.
- Laureys S, Lemaire C, Maquet P, Phillips C, Franck G. Cerebral metabolism during vegetative state and after recovery to consciousness. *J Neurol Neurosurg Psychiatry* 1999; 67: 121.
- Boly M, Faymonville ME, Peigneux P, et al. Auditory processing in severely brain injured patients: differences between the minimally conscious state and the persistent vegetative state. *Arch Neurol* 2004; 61: 233–38.
- Agardh CD, Rosen I, Ryding E. Persistent vegetative state with high cerebral blood flow following profound hypoglycemia. *Ann Neurol* 1983; 14: 482–86.

- 62 Laureys S, Faymonville ME, Goldman S, et al. Impaired cerebral connectivity in vegetative state. In: Gjedde A, Hansen SB, Knudsen GM, Paulson OB, eds. *Physiological imaging of the brain with PET*. San Diego: Academic Press, 2000: 329–34.
- 63 Baars B, Ramsay T, Laureys S. Brain, conscious experience and the observing self. *Trends in Neurosci* 2003; 26: 671–75.
- 64 Rudolf J, Sobesky J, Grond M, Heiss WD. Identification by positron emission tomography of neuronal loss in acute vegetative state. *Lancet* 2000; 355: 155.
- 65 Laureys S, Faymonville ME, Luxen A, Lamy M, Franck G, Maquet P. Restoration of thalamocortical connectivity after recovery from persistent vegetative state. *Lancet* 2000; 355: 1790–91.
- 66 Gould E, Reeves AJ, Graziano MS, Gross CG. Neurogenesis in the neocortex of adult primates. *Science* 1999; 286: 548–52.
- 67 Laureys S, Faymonville ME, Moonen G, Luxen A, Maquet P. PET scanning and neuronal loss in acute vegetative state. *Lancet* 2000; 355: 1825–26.
- 68 de Jong B, Willemsen AT, Paans AM. Regional cerebral blood flow changes related to affective speech presentation in persistent vegetative state. *Clin Neurol Neurosurg* 1997; 99: 213–16.
- 69 Laureys S, Faymonville ME, Peigneux P, et al. Cortical processing of noxious somatosensory stimuli in the persistent vegetative state. *Neuroimage* 2002; 17: 732–41.
- 70 Laureys S, Faymonville ME, Degueldre C, et al. Auditory processing in the vegetative state. *Brain* 2000; 123: 1589–601.
- 71 Schiff N, Ribary U, Plum F, Llinás R. Words without mind. *J Cogn Neurosci* 1999; 11: 650–56.
- 72 Laureys S, Faymonville M, Ferring M, et al. Differences in brain metabolism between patients in coma, vegetative state, minimally conscious state and locked-in syndrome. *Eur J Neurol* 2003; 10 (suppl 1): 224.
- 73 Andreasen NC, O'Leary DS, Cizadlo T, et al. Remembering the past: two facets of episodic memory explored with positron emission tomography. *Am J Psychiatry* 1995; 152: 1576–85.
- 74 Gusnard DA, Raichle ME. Searching for a baseline: functional imaging and the resting human brain. *Nat Rev Neurosci* 2001; 2: 685–94.
- 75 Fiset P, Paus T, Daloz T, et al. Brain mechanisms of propofol-induced loss of consciousness in humans: a positron emission tomographic study. *J Neurosci* 1999; 19: 5506–13.
- 76 Kaisti KK, Langsjo JW, Aalto S, et al. Effects of sevoflurane, propofol, and adjunct nitrous oxide on regional cerebral blood flow, oxygen consumption, and blood volume in humans. *Anesthesiology* 2003; 99: 603–13.
- 77 Maquet P, Peters J, Aerts J, et al. Functional neuroanatomy of human rapid-eye-movement sleep and dreaming. *Nature* 1996; 383: 163–66.
- 78 Maquet P, Faymonville ME, Degueldre C, et al. Functional neuroanatomy of hypnotic state. *Biol Psychiatry* 1999; 45: 327–33.
- 79 Rainville P, Hofbauer RK, Paus T, Duncan GH, Bushnell MC, Price DD. Cerebral mechanisms of hypnotic induction and suggestion. *J Cogn Neurosci* 1999; 11: 110–25.
- 80 Minoshima S, Giordani B, Berent S, Frey KA, Foster NL, Kuhl DE. Metabolic reduction in the posterior cingulate cortex in very early Alzheimer's disease. *Ann Neurol* 1997; 42: 85–94.
- 81 Salmon E, Collette F, Degueldre C, Lemaire C, Franck G. Voxel-based analysis of confounding effects of age and dementia severity on cerebral metabolism in Alzheimer's disease. *Hum Brain Mapp* 2000; 10: 39–48.
- 82 Aupee AM, Desgranges B, Eustache F, et al. Voxel-based mapping of brain hypometabolism in permanent amnesia with PET. *Neuroimage* 2001; 13: 1164–73.
- 83 Vogt BA, Finch DM, Olson CR. Functional heterogeneity in cingulate cortex: the anterior executive and posterior evaluative regions. *Cereb Cortex* 1992; 2: 435–43.
- 84 Lou HC, Luber B, Crupain M, et al. Parietal cortex and representation of the mental Self. *Proc Natl Acad Sci USA* 2004; 101: 6827–32.
- 85 Schiff ND, Plum F, Rezaei AR. Developing prosthetics to treat cognitive disabilities resulting from acquired brain injuries. *Neurol Res* 2002; 24: 116–24.
- 86 Hirsch J, Kamal A, Moreno D, et al. fMRI reveals intact cognitive systems for two minimally conscious patients. *Abstr Soc Neurosci* 2001; 27: 1397.
- 87 Bekinschtein T, Niklison J, Sigman L, et al. Emotion processing in the minimally conscious state. *J Neurol Neurosurg Psychiatry* 2004; 75: 788.
- 88 Gutling E, Isenmann S, Wichmann W. Electrophysiology in the locked-in syndrome. *Neurology* 1996; 46: 1092–101.
- 89 Laureys S, van Eeckhout P, Ferring M, et al. Brain function in acute and chronic locked-in syndrome. Proceedings of the 9th Annual Meeting of the Organisation for Human Brain Mapping (OHBM); 2003 June 18–22; New York, USA. *Neuroimage CD ROM* 2003; 19 (suppl 1).
- 90 Leon-Carrion J, van Eeckhout P, Dominguez-Morales Mdel R, Perez-Santamaria FJ. The locked-in syndrome: a syndrome looking for a therapy. *Brain Inj* 2002; 16: 571–82.
- 91 Laureys S, Peigneux P, Goldman S. Brain imaging. In: D'haenen H, den Boer JA, Willner P, eds. *Biological psychiatry*. New York: John Wiley & Sons Ltd, 2002: 155–66.
- 92 Friston KJ. Analysing brain images: principles and overview. In: Frackowiak RSJ, Friston KJ, Frith CD, Dolan RJ, Mazziotta JC, eds. *Human brain function*. San Diego: Academic Press, 1997: 25–41.
- 93 Posner MI, Raichle ME. *Images of the brain: images of mind*. New York: Scientific American Library, 1994: 53–81.
- 94 Wu HM, Huang SC, Hattori N, et al. Selective metabolic reduction in gray matter acutely following human traumatic brain injury. *J Neurotrauma* 2004; 21: 149–61.
- 95 Hamlin GP, Cernak I, Wixey JA, Vink R. Increased expression of neuronal glucose transporter 3 but not glial glucose transporter 1 following severe diffuse traumatic brain injury in rats. *J Neurotrauma* 2001; 18: 1011–18.
- 96 Goodman JC, Valadka AB, Gopinath SP, Uzura M, Robertson CS. Extracellular lactate and glucose alterations in the brain after head injury measured by microdialysis. *Crit Care Med* 1999; 27: 1965–73.
- 97 Hovda DA, Becker DP, Katayama Y. Secondary injury and acidosis. *J Neurotrauma* 1992; 9 (suppl 1): S47–60.
- 98 Herscovitch P, Auchus AP, Gado M, Chi D, Raichle ME. Correction of positron emission tomography data for cerebral atrophy. *J Cereb Blood Flow Metab* 1986; 6: 120–24.
- 99 Videen TO, Perlmutter JS, Mintun MA, Raichle ME. Regional correction of positron emission tomography data for the effects of cerebral atrophy. *J Cereb Blood Flow Metab* 1988; 8: 662–70.
- 100 Meltzer CC, Kinahan PE, Greer PJ, et al. Comparative evaluation of MR-based partial-volume correction schemes for PET. *J Nucl Med* 1999; 40: 2053–65.
- 101 Meltzer CC, Zubieta JK, Links JM, et al. MR-based correction of brain PET measurements for heterogeneous gray matter radioactivity distribution. *J Cereb Blood Flow Metab* 1996; 16: 650–58.
- 102 Quarantelli M, Berkouk K, Prinster A, et al. Integrated software for the analysis of brain PET/SPECT studies with partial-volume-effect correction. *J Nucl Med* 2004; 45: 192–201.
- 103 Sakatani K, Murata Y, Fukaya C, Yamamoto T, Katayama Y. BOLD functional MRI may overlook activation areas in the damaged brain. *Acta Neurochir Suppl* 2003; 87: 59–62.
- 104 Gsell W, De Sadeleer C, Marchalant Y, MacKenzie ET, Schumann P, Dauphin F. The use of cerebral blood flow as an index of neuronal activity in functional neuroimaging: experimental and pathophysiological considerations. *J Chem Neuroanat* 2000; 20: 215–24.
- 105 Hamzei F, Knab R, Weiller C, Rother J. The influence of extra- and intracranial artery disease on the BOLD signal in fMRI. *Neuroimage* 2003; 20: 1393–99.
- 106 Rossini PM, Altamura C, Ferretti A, et al. Does cerebrovascular disease affect the coupling between neuronal activity and local haemodynamics? *Brain* 2004; 127: 99–110.
- 107 Freire L, Mangin JF. Motion correction algorithms may create spurious brain activations in the absence of subject motion. *Neuroimage* 2001; 14: 709–22.
- 108 Brett M, Leff AP, Rorden C, Ashburner J. Spatial normalization of brain images with focal lesions using cost function masking. *Neuroimage* 2001; 14: 486–500.
- 109 Phelps ME. Inaugural article: positron emission tomography provides molecular imaging of biological processes. *Proc Natl Acad Sci USA* 2000; 97: 9226–33.
- 110 Bernat JL. *Clinical research. Ethical issues in neurology* (2nd edn). Boston: Butterworth Heinemann, 2002: 469–94.
- 111 Karlawish JH. Research involving cognitively impaired adults. *N Engl J Med* 2003; 348: 1389–92.
- 112 Bigatello LM, George E, Hurford WE. Ethical considerations for research in critically ill patients. *Crit Care Med* 2003; 31: S178–81.
- 113 Phipps EJ. Research ethics in head trauma rehabilitation. *J Head Trauma Rehabil* 2000; 15: 965–68.
- 114 Oransky I. Neurologists say Florida woman is very unlikely to recover. *Lancet Neurol* 2003; 2: 715.
- 115 Fins JJ. Constructing an ethical stereotaxy for severe brain injury: balancing risks, benefits and access. *Nat Rev Neurosci* 2003; 4: 323–27.